

SHORT REPORT

Fungal corneal ulcers of onion harvesters in southern Taiwan

Shang-Ho Lin, Chang-Ping Lin, Hwei-Zu Wang, Rong-Kung Tsai, Chi-Kung Ho

Abstract

Fungal corneal ulcers related to agriculture has been reported throughout the world, especially in tropical areas. Most of them were sporadic and had histories of ocular trauma or use of topical corticosteroids and topical antibiotics. Five onion harvesters had fungal corneal ulcers during the same harvest period in Southern Taiwan. The authors think that this is the first report of a group occurrence relating to agricultural workers. Although all of the patients improved after medical and surgical management, their vision was greatly decreased. It is suggested that the tropical climate, the harvest procedure, the characteristic monsoon, and lack of eye protection were involved. Therefore, the importance of the eye protection, hygiene education, and improving medical care to reduce the occurrence of fungal corneal ulcer in agriculture workers must be emphasised.

(*Occup Environ Med* 1999;56:423-425)

Keywords: fungal corneal ulcer; agriculture; monsoon

Fungal keratitis related to agriculture has been reported throughout the world.¹⁻³ Most cases reported were sporadic and had histories of ocular trauma. Previous steroids or topical antibiotics use after trauma also contributed to fungal keratitis.¹⁻⁶ The clinical course is long and serious. Delay in recognition or in treatment of this infection usually results in blindness.^{3,4}

Liesegang *et al* had emphasised the frequent occurrence of fungal keratitis related to agriculture in dry and windy months in south Florida.¹ Similar conditions exist for agricultural workers in other countries, such as Thailand, India, and Taiwan.^{2,7} Because of unusual weather conditions during the harvest period, which lasts from December to April, we report five cases that occurred during the same harvest as a group occurrence of fungal keratitis among onion harvesters in the Heng-Chun peninsula of the Southern Taiwan. This area is tropical; the monsoon wind blows from October to April southeasterly along the central mountain chain of Taiwan then downward to

the Heng-Chun peninsula. It is strong, and may reach 20 m/s.⁸

Due to the characteristic climate and the onion harvesting procedure, fungal keratitis has become a particular occupational disease in the southern Taiwan.

Case report

Table 1 summarises the clinical characteristics and the laboratory findings of the five onion harvesters with fungal corneal ulcers. There were three women and two men and their ages ranged from 44 to 69. All of them had complaints of a persistent gritty sensation or pain of their eyes and they were admitted to the ophthalmic ward of the Kaohsiung Medical College Hospital through the ophthalmic outpatients department by referral from other hospitals in March and April, 1997. Patients 2 and 3 have diabetes mellitus. Only patient 1 denied ocular trauma. The others complained of corneal trauma by pieces of onion skin or plant leaves. Before admission, three of them had been treated with topical antibiotics or corticosteroids.

Examination on admission showed that the visual acuity of the infected eyes of the first three patients was limited to only perception of light. The locations of the corneal ulcers in these cases were central in patients 1, 2, and 3 and peripheral in the others. The fungal hyphae were demonstrated with the KOH wet mount technique in four patients (not in patient 4). Due to the history of trauma and the typical feathery ulcer edge, fungal corneal ulcer was also highly suspected in patient 4. Scrapings from all corneal ulcers were sent for culture on Sabouraud's dextrose agar, which grew *Candida* in patient 1, *Cephalosporium* in patients 2 and 3 (figure) and *Cryptococcus* in patient 4. Patient 5 had a negative fungal culture. After admission they were all treated with topical solutions of amphotericin B and fluconazole.

Intravitreal injection or intracamera injection of fluconazole solution were applied to patients 1, 2, and 3. Due to recurrent corneal ulcer 1 week after discharge, patient 3 was admitted again and oral fluconazole was added for 2 weeks at 150 mg daily. Patients 1, 2, and 3 had received therapeutic penetrating keratoplasty because initial treatment failed to control the infection during the first admission.

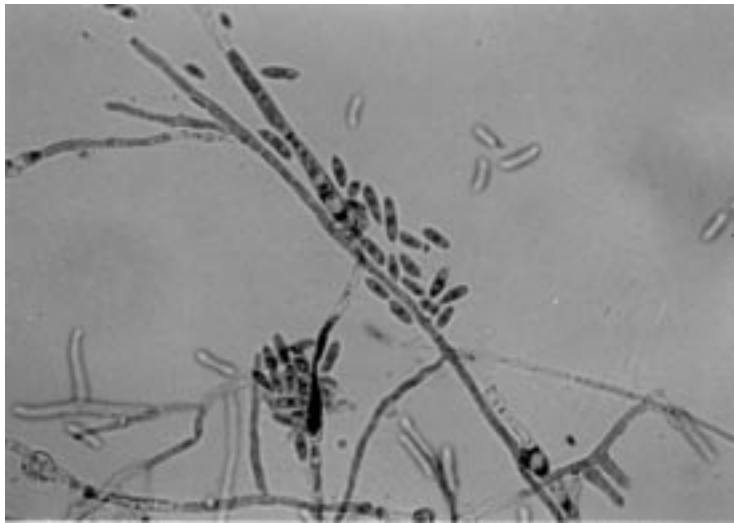
Department of Occupational Medicine of Kaohsiung Medical College Hospital, Kaohsiung, Taiwan, Republic of China
S-H Lin

Department of Ophthalmology of Kaohsiung Medical College Hospital, Kaohsiung, Taiwan, Republic of China
C-P Lin
H-Z Wang
R-K Tsai

Department of Occupational Medicine of Kaohsiung Medical College Hospital and Institute of Graduate Occupational Safety and Health of Kaohsiung Medical College, Kaohsiung, Taiwan, Republic of China
C-K Ho

Correspondence to:
Dr Chi-Kung Ho,
Department of Occupational Medicine of Kaohsiung Medical College Hospital,
100 Shih-Chuan First Road,
Kaohsiung City, Taiwan,
Republic of China.

Accepted 4 December 1998



Preparation in lactophenol cotton blue of *Cephalosporium* species isolated from the corneal ulcer of patient 3. (Original magnification $\times 400$.)

Case 1 also received anterior vitrectomy for endophthalmitis. The corneal infections resolved after medical and surgical management but patients were left with residual visual impairment at one month after discharge.

Discussion

In the past several decades, the number of cases of fungal keratitis reported has been increasing, perhaps attributable to the increased use of topical corticosteroids, broad spectrum antibiotics, increased awareness, and better diagnostic techniques.^{4-5,9} If patients are not promptly or properly treated, severe diminution in vision or even loss of the eyeball can result.^{3,4,6} Therefore, early diagnosis is of importance and corneal scrapings for elements of fungal hyphae must be examined with gram, Giemsa, or KOH preparations.^{6,9-11} Vajpayee *et al* reported "direct microscopic examination of a KOH wet mount preparation of corneal scrapings is a rapid reliable, and superior technique of laboratory diagnosis, especially for a small rural eye care health centre in a developing

country".¹⁰ Also, materials obtained from corneal ulcers should be inoculated on sabouraud dextrose agar or brain-heart infusion broth to confirm a diagnosis of fungal keratitis and to determine the in vitro susceptibility of the fungal strain to different antifungal compounds.^{6,9} Clinically a fungal infection should be considered in all cases of persistent corneal ulceration or in ulcers with a history of trauma by vegetable materials. As fungal keratitis is a sight threatening disease, a prompt, accurate diagnosis is essential for its successful management.

The most common causes of fungal keratitis are *Aspergillus*, *Fusarium* and *Candida*.^{1,2,4,6} Although *Cephalosporium* has been reported to cause keratitis and exogenous endophthalmitis in the southern part of the United States and India, it is an infrequent human pathogen, and usually occurs after trauma, especially when vegetable matter and wood chips have been involved in the injury.^{1,2,6} Fincher *et al* summarised 17 cases of *Cephalosporium* keratitis and endophthalmitis, 13 of the patients had a history of trauma.¹³ Two of our patients had *Cephalosporium* corneal ulcer and both had been injured by pieces of onion skin. The optimal treatment regimen for *Cephalosporium* infection is not yet well defined because of the rarity of infection due to these organisms and because many reports antedate effective antifungal treatment.^{5,13-15} Fungal keratitis due to *Cephalosporium* has been reported to recur as a posterior corneal abscess.¹⁴ Our patients with *Cephalosporium* corneal ulcer received therapeutic penetrating keratoplasty even after vigorous medical treatment. Although the corneal infections were controlled, the patients' residual vision was markedly diminished. Patient 3 even took oral fluconazole for severe fungal corneal ulcer.¹⁶

Patients 2 and 3 worked in the same onion field and both were injured by pieces of onion skin during work. The organisms isolated from their corneal ulcers were *Cephalosporium* species. This result reminds us of the possibility of a relation between the occurrence of *Cephalosporium* in the onion fields and ocular infection.

Table 1 Clinical characteristics and laboratory findings of onion harvesters with fungal corneal ulcers

	Patient No				
	1	2	3	4	5
Age/sex	48/F	54/F	44/M	68/M	69/F
Admission date	22 April 1997	29 April 1997	24 April 1997	28 March 1997	11 April 1997
Systemic disease	Nil	DM and HT	DM	Nil	HT
Previous ocular disease	Nil	Pterygium	Nil	Nil	Cataract
Corneal trauma	Nil	Pieces of onion skin	Pieces of onion skin	Pieces of onion skin	Plant leaf
Use of antibiotics or corticosteroids before referral	+/+	+/+	+/+	-/-	-/-
Type of infection	Corneal ulcer (OS), endophthalmitis (OS)	Corneal ulcer (OS)	Corneal ulcer (OD)	Corneal ulcer (OS)	Corneal ulcer (OS)
Location of corneal infection	Central	Central	Central	Peripheral	Peripheral
Culture of organism by corneal scraping	<i>Candida</i>	<i>Cephalosporium</i> species	<i>Cephalosporium</i> species	<i>Cryptococcus</i>	(-)
KOH wet mounting preparation	Hyphae (+)	Hyphae (+)	Hyphae (+)	(-)	Hyphae (+)
Treatment:					
Medical	AMB+Flu topicals, Flu:IVI	AMB+Flu topicals, Flu:ICI	AMB+Flu topicals, Flu:ICI;IVI, Flu 150 mg \times 14 days	AMB+Flu topicals	AMB+Flu topicals
Surgical	PK, Anterior vitrectomy	PK	PK	(-)	(-)
Outcome	Cured vision:PL	Cured vision:PL	Cured vision FC/30 cm	Cured vision 6/60	Cured vision 6/30

DM=diabetes mellitus; HT=hypertension; PL=perception of light; FC=finger counting; AMB=Amphotericin B; Flu=Fluconazole; IVI=intravitreal injection; PK=penetrating keratoplasty; OS=left eye; ICI=intracamera injection; OD=right eye.

This requires further ecological investigation, such as that performed by Cuero in bean, corn, or sugar cane fields in Colombia.¹⁷

To our knowledge, these fungal corneal ulcers of onion harvesters constitute the first report of the group occurrence of ulcers in agricultural workers. The evidence suggests their infections are strongly related to the tropical environment, the harvest procedure, the windy weather, and most importantly the lack of eye protection. Similar to other tropical areas, most of the rural agricultural workers of the Heng-Chuan peninsula are at risk of developing fungal corneal ulcers after exposure to the environment and corneal trauma while working in the fields. The harvest procedure of onions can be separated into four steps: lifting, cutting leaves and roots, categorising size, and finally packing, which are all performed by manual labour with hands and knives. After lifting all onions are put under an iron awning at the side of the farm where the other steps are carried out. According to the onion harvesters' descriptions, they do not wear any goggles for protection but only plastic gloves while they are working during the harvesting procedures. Dust with pieces of onion skin sometimes falls into their eyes as strong monsoon winds are blowing, and they often complain of discomfort of their eyes. They usually seek medical advice too late because of poor education and a lack of ophthalmic clinics.

Due to the prevalence of corneal ulcers in the agricultural workers, we consider that educating them to notice fungal corneal ulcers and educating them to avoid ocular trauma is very important. Wearing a pair of protective spectacles may reduce the possibility of corneal injury, especially if working in windy weather. If

a foreign body injures the eye, the workers should be told not to rub their eyes with their hands or anything else, and medical advice should be sought immediately. In conclusion, wearing protective spectacles, education about hygiene, and improvements in provision of medical care will reduce the occurrence of fungal corneal ulcers in agricultural workers.

- 1 Leisegang TJ, Forster JF. Spectrum of microbial keratitis in south Florida. *Am J Ophthalmol* 1980;**90**:38–47.
- 2 Sharma JCA. Prevalence of fungal corneal ulcers in northern India. *Infection* 1994;**22**:207–9.
- 3 Polack FM, Kaufman HE, Newmark E. *Keratomycosis Archive Ophthalmology* 1971;**85**:410–16.
- 4 Naumann GOH, Green WR, Zimmerman LE. Mycotic keratitis: a histopathologic study of 73 cases. *Am J Ophthalmol* 1967;**64**:668–82.
- 5 Byers JL, Holland MG, Allen JH. Cephalosporium keratitis. *Am J Ophthalmol* 1960;**49**:267–9.
- 6 Thomas P A. Mycotic keratitis—an underestimated mycosis. *J Med Vet Mycol* 1994;**32**:235–56.
- 7 Imwidthaya P. Mycotic keratitis in Thailand. *J Med Vet Mycol* 1995;**33**:81–2.
- 8 Chen YF. *Coastal vegetation of Kenting National Park*. Taiwan, ROC: Kenting National Park Headquarters, Construction and Planning Administration, Ministry of the Interior, 1985;29–30. (In Chinese.)
- 9 Ishibashi Y, Hommura S, Matsumoto Y. Direct examination v culture of biopsy specimens for the diagnosis of keratomycosis. *Am J Ophthalmol* 1987;**103**:636–40.
- 10 Vojpayee RB, Surendra KA, Sandramouli S, et al. Laboratory diagnosis of keratomycosis: comparative evaluation of direct microscopy and culture results. *Ann Ophthalmol* 1993;**25**:68–71.
- 11 Winchester K, Mathers WD, Sutpbjn J E. Diagnosis of aspergillus keratitis in vivo with confocal microscopy. *Cornea* 1997;**16**:27–31.
- 12 Rosa R H, Miller D, Alfonso E C. The changing spectrum of fungal keratitis in south Florida. *Ophthalmology* 1994;**101**:1005–13.
- 13 Fincher RM, Fisher JF, Lovell RD, et al. Infection due to the fungus acremonium (cephalosporium). *Medicine* 1991;**70**:398–409.
- 14 Forster RK, Rebell G, Stiles W. Recurrent keratitis due to acremonium potronii. *Am J Ophthalmol* 1975;**79**:126–8.
- 15 Kennedy SM. Keratitis due to the fungus acremonium (cephalosporium). *Eye* 1994;**8**:692–4.
- 16 Thakar M. Oral fluconazole therapy for keratomycosis. *Acta Ophthalmol* 1994;**72**:765–7.
- 17 Cuero RG. Ecological distribution of Fusarium Solani and its opportunistic action related to mycotic keratitis in Cali, Colombia. *J Clin Microbiol* 1980;**12**:455–61.



Fungal corneal ulcers of onion harvesters in southern Taiwan.

S H Lin, C P Lin, H Z Wang, et al.

Occup Environ Med 1999 56: 423-425

doi: 10.1136/oem.56.6.423

Updated information and services can be found at:

<http://oem.bmj.com/content/56/6/423>

References

These include:

Article cited in:

<http://oem.bmj.com/content/56/6/423#related-urls>

Email alerting service

Receive free email alerts when new articles cite this article. Sign up in the box at the top right corner of the online article.

Notes

To request permissions go to:

<http://group.bmj.com/group/rights-licensing/permissions>

To order reprints go to:

<http://journals.bmj.com/cgi/reprintform>

To subscribe to BMJ go to:

<http://group.bmj.com/subscribe/>