

Pulmonary fibrosis in asbestos insulation workers with lung cancer: a radiological and histopathological evaluation

H M KIPEN,* RUTH LILIS, Y SUZUKI, J A VALCIUKAS, I J SELIKOFF

From the Environmental Sciences Laboratory, Mount Sinai School of Medicine of the City University of New York, New York, USA

ABSTRACT This study was undertaken to determine the relation between radiographic and histological manifestations of pulmonary asbestosis (interstitial fibrosis) in insulation workers who had died of lung cancer. Of 450 confirmed deaths from lung cancer a chest radiograph suitable for determining evidence of pneumoconiosis was obtained in 219. Of these cases, 138 also had a tissue specimen submitted that was suitable for histological study to determine the extent of histological fibrosis. There was a significant albeit limited correlation between the radiographic and histological findings ($r = 0.27$, $p < 0.0013$). All 138 cases had histological evidence of parenchymal fibrosis; in 25 (18%), however, there was no radiographic evidence of parenchymal fibrosis. In 10 cases (7%) both parenchymal and pleural disease were undetectable on the radiograph. Thus a negative chest radiograph does not exclude the presence of interstitial fibrosis (asbestosis) in a substantial proportion of insulation workers previously exposed to asbestos who develop lung cancer.

Cancer of the lung is a leading cause of death in workers exposed to asbestos.¹⁻⁵ For example, it has been found to account for as much as one fifth (21%) of deaths in a large prospective mortality study of asbestos insulation workers.⁶

In individuals with lung cancer there are many different ways to assess retrospectively whether or not they have had significant exposure to asbestos. In the clinical setting exposure is often inferred from the presence of non-malignant effects of asbestos exposure: pleural fibrosis and interstitial pulmonary fibrosis.

Histopathologically, asbestosis includes diffuse interstitial pulmonary fibrosis developing as a consequence of inhaling asbestos fibres; it is usually associated with the presence of asbestos bodies, although these may vary in number and ease of demonstration.⁷ Clinical studies in man, however, often do not use histopathological criteria for the diagnosis of asbestosis but the more easily obtained and less invasive chest x ray (and clinical) data. Such radio-

logical and clinical evidence has been reported to be less sensitive to the presence of asbestosis (and other types of interstitial fibrosis) than histopathological examination.^{8,9} This study examines further the relation between the radiographic and histopathological evidence of asbestosis in a population of asbestos insulation workers with lung cancer.

As part of a continuing cohort mortality study of 17800 members of the insulation workers' union (International Association of Heat and Frost Insulators and Asbestos Workers, AFL-CIO, CLC), we examined deaths from lung cancer which occurred between January 1967 and September 1983.

Methods

IDENTIFICATION OF CASES FOR ANALYSIS

On learning from the union of a member's death, we requested death certificates, medical records, chest radiographs, pathology reports, and surgical necropsy pathological specimens, or both, from hospitals and attending physicians. These were reviewed and only after pathological confirmation of the presence of primary lung carcinoma was a case eligible for the further analyses described here.

*Present address: Department of Environmental and Community Medicine, UMDNJ—Rutgers Medical School, Piscataway, NJ 08854.

Accepted 14 April 1986

RADIOLOGICAL AND PATHOLOGICAL ASSESSMENT

Of the 450 pathologically confirmed lung cancers observed by September 1983, we obtained chest radiographs from 229. Of these, 219 were adequate for assessing interstitial pulmonary fibrosis. The chest radiographs had been taken at various times, anywhere from immediately preceding death to a few years before. When multiple films were available, the film that showed the earliest evidence of carcinoma was interpreted for the purposes of this study. To avoid confusion of radiological changes related to tumour with non-malignant changes of fibrosis, the radiological abnormalities in the hemithorax contralateral to the side of the tumour were interpreted according to the ILO 1980 International Classification of Radiographs of Pneumoconioses.¹⁰

According to the International Classification, category of profusion is based on assessment of the number of small opacities per surface unit by comparison with standard radiographs. Use of the ILO International Classification allows stratification of radiologically detectable small opacities (interstitial fibrosis) into the 12 categories ranging from 0/- to 3/4 (0/0, 0/1, 1/0, 1/1, 1/2, etc). Pleural changes were also graded in the standard fashion regarding width and extent according to the International Classification.

Initial chest x ray readings (by RL and HK) were made in the absence of any clinical information except for the date and cause of death—lung cancer. Where no tumour was radiologically evident, where previous therapeutic intervention was clearly evident, or where a diagnosis other than lung cancer and asbestosis was considered, clinical and pathology records were reviewed to provide information about the side of the cancer. Films taken before the onset of terminal illness often helped. On six films, the parenchyma was assessed on the side of the tumour because of obscuring contralateral disease such as pleural effusion or cardiac enlargement. On seven additional films, tumours were either not seen or were present

bilaterally, so a contralateral side could not be identified. In all these cases we were confident of the accuracy of the (possibly) ipsilateral reading, and these cases are included in the analysis. All findings were reviewed separately with a third reader (IJS), and the consensus of the three readers is reported.

All cases have, by definition, a pathological diagnosis of lung cancer by virtue of histological examination of tumour tissue. Adequate tissue for microscopic assessment of the degree of parenchymal fibrosis, however, was not always obtained, as when the diagnosis of neoplasm was established by bronchoscopic biopsy. Of the 219 cases with adequate radiological data, 138 had enough non-malignant pulmonary tissue submitted as part of a surgical specimen, a biopsy, or a necropsy to permit the assessment of the presence or absence of diffuse interstitial pulmonary fibrosis and its degree, on the level of light microscopy. It is in these 138 cases that we could compare the radiological and microscopical evidence of asbestosis. Consistent with our tissue sources, pathological analysis was often done on the side ipsilateral to the tumour.

Grading of the degree of parenchymal fibrosis was performed by YS according to a seven point scale:

None—No histological evidence of interstitial fibrosis.

Minimal—Rare presence of focal, mild thickening of the interstitium.*

Mild—Presence of multiple foci of an increased amount of fibrosis in the interstitium.

Moderate—Interstitial fibrosis associated with obliteration of alveoli and showing early consolidation.

Severe—Pronounced fibrosis associated with consolidation, honeycomb formation, and obliteration of airways.

*The interstitium includes the peribronchiolar, perivascular, alveolar septal, and subpleural connective tissues. Interestingly, however, asbestos related diffuse pulmonary interstitial fibrosis starts in the peribronchiolar connective tissue.

Histopathological and radiological findings. (Complete absence of x ray changes including pleural abnormalities shown in parentheses)

X ray profusion of small opacities	Histopathological fibrosis				Totals
	No of cases				
	Minimal	Mild	Moderate	Severe	
0/0			5(2)		5
0/1		2(1)	11(6)	7(1)	20
1/0	1	1	5	6	13
1/1	1	2	20	16	39
1/2			6	6	12
2/1		1	5	7	13
2/2		1	10	7	18
2/3			1	3	4
3/2			2	5	7
3/3			1	6	7
Totals	2	7	66	63	138

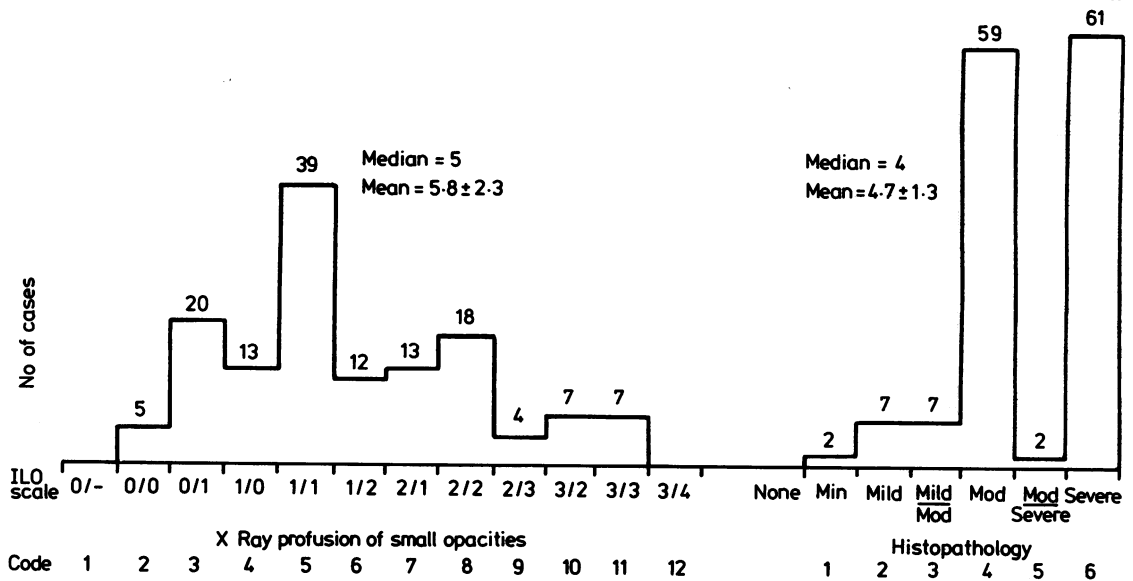


Fig 1 Distribution patterns of radiological small irregular opacities (median and mean \pm SD derived from the 1 to 12 code) and of histopathological changes (median and mean \pm SD derived from the 1 to 6 code used for numerical transformation of severity of fibrosis). (See text.)

Intermediate categories of mild-moderate and moderate-severe were read in a few cases, yielding seven gradations of fibrosis. (For representational purposes only the four major categories are shown in the table, with intermediate readings included in the next higher category.)

STATISTICAL ANALYSIS

The major radiographic variable analysed was the category of profusion of small irregular parenchymal opacities. Categories of profusion beginning with 0/- were assigned sequential integer values from 1 to 12 coded such that 0/- = 1, 0/0 = 2, 0/1 = 3, and so on up to 3/4 = 12. Pathological gradings of fibrosis from "none" to "severe" were similarly assigned successive integer values from 0 to 6.

The presence or absence of asbestos related pleural thickening, including diaphragmatic plaques, was the other major radiographic variable analysed. The width of tangential pleural thickening was also scored and treated as a separate variable.

Descriptive statistics were calculated for each variable. Because the variables were ratings, non-parametric correlational procedures were used. Spearman correlation coefficients were calculated for all pair combinations of variables using the SAS program.

Results

Of the 138 cases, 113 (82%) had radiologically detectable small irregular opacities (ILO profusion equal to or greater than 1/0). The mean degree of profusion was 5.8 (SD 2.3), corresponding to between 1/1 and 1/2 on the ILO scale (fig 1).

In all 138 cases there were histopathological signs of diffuse interstitial fibrosis. The mean degree was 4.7 (SD 1.3), corresponding to between moderate and severe on the scale (fig 1). One or more asbestos bodies were seen in 94% of cases (130/138).

Profusion of radiologically detectable small irregular opacities was significantly correlated with the degree of microscopic fibrosis ($r = 0.27$, $p < 0.0013$) (fig 2 and table).

Of the 138 cases, 94 (68%) had a radiologically detectable pleural abnormality (circumscribed or diffuse pleural fibrosis, calcification).

The presence/absence of any pleural abnormality on the chest radiograph was not significantly correlated with the profusion of irregular opacities ($r = 0.09$, $p = 0.29$) nor with the extent of microscopic fibrosis ($r = 0.12$, $p = 0.16$).

The width of tangential pleural thickening was significantly correlated with profusion of small irregular opacities ($r = 0.33$, $p < 0.0075$) but not with microscopic fibrosis ($r = -0.09$, $p = 0.46$).

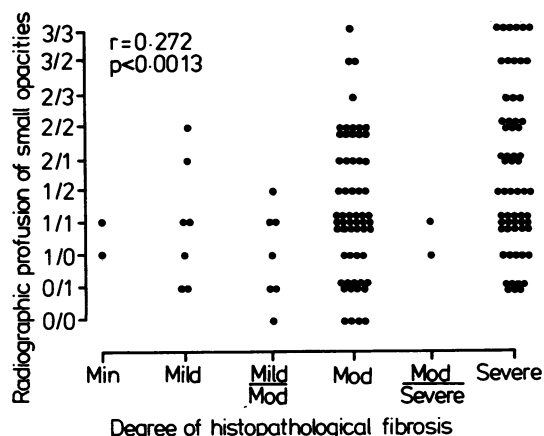


Fig 2 Correlation between radiographic and histopathological assessments of interstitial pulmonary fibrosis in 138 insulation workers with lung cancer ($r = 0.27$, $p < 0.0013$).

In 18% of the cases (25/138) interstitial pulmonary fibrosis of asbestosis was not radiographically detectable (small irregular opacities not seen) although diffuse interstitial fibrosis was invariably present on microscopic examination (138/138) (table).

Pleural thickening and plaques were also absent in 10 of the 25 cases without radiographically detectable interstitial fibrosis, making 7% of the 138 films negative for any evidence of benign asbestos related pleuropulmonary changes. Pulmonary fibrosis by histopathological assessment was moderate or severe in nine of these ten.

Duration from onset of asbestos work to death was significantly correlated with radiological profusion of small irregular opacities ($r = 0.24$, $p < 0.006$) but not

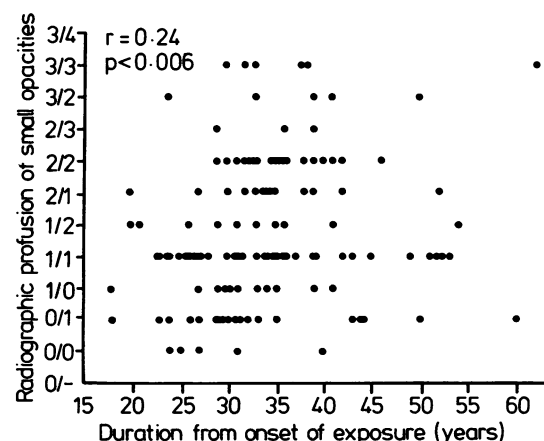


Fig 3 Correlation between duration from onset of insulation work (in years) and radiographic profusion of small irregular opacities ($r = 0.24$, $p < 0.006$).

with the degree of microscopic fibrosis ($r = 0.11$, $p = 0.22$) (fig 3).

Duration from onset of asbestos work to death in the 25 radiographically negative cases (32.8 y) was not significantly less than that of the group as a whole ($34.1 \text{ y} \pm 8.4 \text{ y}$).

Discussion

The first reports associating lung cancer with asbestosis appeared in 1935^{11 12} and many studies since then have convincingly shown an increased incidence of lung cancer in asbestos exposed workers.¹⁻⁵ All common cell types occur more frequently.^{13 14}

In this large study of exposed asbestos insulation workers parenchymal fibrosis was present in all those with lung cancer whose pulmonary tissues were microscopically examined. It has been estimated that asbestos exposures in this group were generally in the range of 4-15 fibres per ml.¹⁵ Because of the large size of this cohort (17 800, with 485 of the first 2275 deaths due to lung cancer⁶), it seems probable that a large majority (perhaps all) of the lung cancers developing in similarly exposed workers will occur in the presence of microscopic fibrosis. This is confirmed by the recent report that 90% of a cohort of British asbestos factory workers who died with lung cancer had histological evidence of asbestosis.⁵ Radiological data were not reported for this group.

In the insulation workers whom we are following up, an increasing radiographic profusion of small opacities was found with increasing duration from onset of exposure. Longer exposures presumably represent greater cumulative exposure to asbestos dust. No such correlation was found between duration from onset of exposure and the pathological grading. This may be explained by the high proportion of cases with moderate or severe fibrosis (93%). Most of these cases had probably passed some relative threshold of exposure beyond which moderate fibrosis usually develops. Analysis of groups with shorter duration from onset of exposure (10 to 20 years) might well yield a higher correlation between the amount of fibrosis on histopathological study and the duration from onset as a measure of exposure.

It is well known that for interstitial pulmonary fibrosis to become radiologically detectable, a certain amount of fibrotic change has to have developed; the summation effect will then produce the irregular opacities visible on the posteroanterior chest x ray film, allowing the diagnosis of interstitial pulmonary fibrosis to be made. The same summation effect operates in the case of small rounded opacities, characteristic of silicosis or coal worker's pneumoconiosis. Unless a certain minimum number (and size) of nodules have developed, rounded opacities do not become recognisable on the radiograph.

Interstitial fibrosis was not radiographically detectable in the parenchyma of 25 (18%) of our 138 cases with lung cancer. Pleural abnormalities associated with asbestos exposure (pleural thickening, plaques, or calcification) were also absent in 10 of the 25 cases in whom parenchymal fibrosis was radiologically undetectable, making the presence of asbestos related disease completely hidden (in the absence of tissue examination) in 7% of the 138 cases of lung cancer in this series.

Published reports on the relationship between radiographic and histopathological manifestations of asbestos related disease are sparse. Although no study has previously reported on this relation in individuals with lung cancer, our findings are in accord with two large studies of patients with various interstitial fibroses including asbestosis. From an unselected series of patients with chronic diffuse infiltrative lung disease, six of 58 patients (10%) with asbestosis confirmed by biopsy had normal radiographs.⁸ Similarly, 56 of 354 patients (15.8%) with a pathological diagnosis of interstitial lung disease had normal chest radiographs.⁹ Eight of this second group had asbestosis and the remaining patients had a variety of infiltrative disease on biopsy.

The probability that interstitial fibrosis will not be radiologically detectable in a sizeable proportion of cases of cancer is of considerable significance, especially in the evaluation of a potential aetiological association between exposure to asbestos and a specific lung cancer. Radiographs negative for evidence of asbestosis related findings do not exclude the presence of interstitial pulmonary fibrosis as ascertained by histopathological examination.

In occupational groups with lower asbestos exposure than that in factory and insulation work lung cancer without radiologically detectable parenchymal opacities may represent a larger proportion of cases than in such highly exposed groups. Continuing studies indicate an increased incidence of lung cancer (RR = 2) in family contacts of asbestos products manufacturing workers.¹⁶ The analysis of the pathological data is incomplete at present; however, 17% of these household contacts had parenchymal abnormalities on chest radiography.¹⁷

We are currently investigating the histopathological pulmonary changes in deaths other than those from lung cancer in the insulation worker cohort to see what proportion of workers have evidence of asbestosis, independent of whether or not they developed lung cancer. The question of whether or not asbestosis always precedes lung cancer in subjects exposed to asbestos is unresolved, and our present data do not permit conclusions regarding the aetiological relation between lung cancer and pulmonary asbestosis per se, as distinct from that of concurrence between lung cancer and exposure to asbestos.

Conclusions

We have found that in the presence of lung cancer occurring in asbestos insulation workers with occupational asbestos exposure asbestosis was invariably present when histopathological findings were used as the criterion for diagnosis. Discrepancies in the results of radiological and pathological examination for interstitial fibrosis were present in 18% of those heavily exposed insulators and may be even more frequent at lower levels of exposure. The inclusion of pleural thickening as an indicator of significant asbestos exposure may help to reduce, but will not eliminate, errors made on this basis. These findings indicate the primacy of the history of asbestos exposure, irrespective of the presence or absence of non-malignant x ray changes (asbestosis) when considering lung cancer possibly associated with occupational exposure to asbestos.

References

- 1 Merewether ERA. *Annual report of the chief inspector of factories*. London: HMSO, 1947.
- 2 Doll R. Mortality from lung cancer in asbestos workers. *Br J Ind Med* 1955;12:81-6.
- 3 McDonald JC, Liddell F, Douglas K. Mortality in Canadian miners and millers exposed to chrysotile. *Ann NY Acad Sci* 1979;330:1-9.
- 4 Newhouse ML, Berry G. Patterns of mortality in asbestos factory workers in London. *Ann NY Acad Sci* 1979;330:53-60.
- 5 Newhouse M, Berry G, Wagner JC. Mortality of factory workers in east London 1933-80. *Br J Ind Med* 1985;42:4-11.
- 6 Selikoff IJ, Hammond EC, Seidman H. Mortality experience of insulation workers in the United States and Canada, 1943-1976. *Ann NY Acad Sci* 1979;330:91-116.
- 7 Warnock ML, Kuwahara TJ, Wolery G. The relation of asbestos burden to asbestosis and lung cancer. *Pathology Annual* 1983;18:109-45.
- 8 Epler GR, McLoud TC, Gaensler EA, Mikus JP, Carrington CB. Normal chest roentgenograms in chronic diffuse infiltrative lung disease. *N Engl J Med* 1978;298:934-9.
- 9 Gaensler EA, Carrington CB. Open biopsy for chronic diffuse infiltrative lung disease clinical, roentgenographic, and physiological correlations in 502 patients. *Ann Thorac Surg* 1980;30:411-26.
- 10 International Labour Office. *Guidelines for the use of ILO International Classification of Radiographs of Pneumonconioses*. Geneva; ILO, 1980. (Occupational safety and health series No 22 (rev 80).)
- 11 Lynch KM, Smith WA. Pulmonary asbestosis. III. Carcinoma of lung in asbestos-silicosis. *Am J Cancer* 1935;24:56-64.
- 12 Gloyne SR. Two cases of squamous carcinomas of the lung occurring in asbestosis. *Tubercle* 1935;17:5-10.
- 13 Kannerstein M, Churg J. Pathology of carcinoma of the lung associated with asbestos exposure. *Cancer* 1972;30:14-21.
- 14 Churg A. Lung cancer cell type and asbestos exposure. *JAMA* 1985;253:2984-5.
- 15 Nicholson WJ. Case study 1: asbestos-the TLV approach. *Ann NY Acad Sci* 1976;271:152-69.
- 16 Lilis R, Selikoff IJ. *Asbestos disease in occupationally-exposed workers and household contacts*. Zur Beurteilung der Krebsgefahr durch Asbest Institut für Wasser-, Boden- und Luftthygiene des Bundesgesundheitsamtes. Manfred Fischer und Eckart Meyer (Herausgeber). Munich: MMV Medizin Verlag, 1984:117-120.
- 17 Anderson HA, Lilis R, Daum SM, Selikoff IJ. Asbestosis among household contacts of asbestos factory workers. *Ann NY Acad Sci* 1979;330:387-400.



Pulmonary fibrosis in asbestos insulation workers with lung cancer: a radiological and histopathological evaluation.

H M Kipen, R Lilis, Y Suzuki, et al.

Br J Ind Med 1987 44: 96-100
doi: 10.1136/oem.44.2.96

Updated information and services can be found at:

<http://oem.bmj.com/content/44/2/96>

Email alerting service

These include:

Receive free email alerts when new articles cite this article. Sign up in the box at the top right corner of the online article.

Notes

To request permissions go to:

<http://group.bmj.com/group/rights-licensing/permissions>

To order reprints go to:

<http://journals.bmj.com/cgi/reprintform>

To subscribe to BMJ go to:

<http://group.bmj.com/subscribe/>